

Post-Operative Care

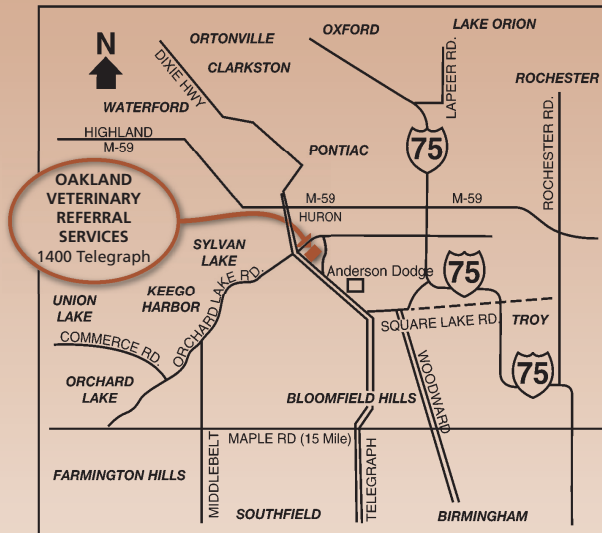
Following surgery, the affected leg may be placed in a soft, padded bandage to reduce discomfort and discourage excessive use of the leg in the early post-operative period. Your pet is usually hospitalized for one night after surgery. The bandage is removed 3-5 days post-operatively and sutures are removed 10-14 days post-operatively. Most animals begin using the affected leg by the time of the suture removal visit, but return of full function may not be seen for several weeks. Physical therapy may be suggested to facilitate early use of the leg. Exercise restrictions should be enforced for 10-12 weeks after surgery.

As mentioned previously, some arthritis is expected even after surgical correction of the patellar luxation. The arthritis generally does not result in lameness, and the prognosis is more favorable in cases without excessive arthritis or growth deformities. After surgery in small breeds of dogs and cats, use of the leg is often normal to near-normal. The prognosis for your pet will be discussed prior to surgery.

If your pet requires surgical correction of both knees, they will generally be done approximately 6 weeks apart. This will allow one leg to recover from surgery and strengthen prior to performing the second side. In some cases, on small dogs and cats, both knees may be operated on at the same time.

Have you been referred? Things to bring at the time of your consultation:

- Recent radiographs and blood work
- Medications your pet is being given



1400 Telegraph Road
Bloomfield Hills, MI 48302
(248) 334-6877

www.OVRS.com

Oakland Veterinary Referral Services



SURGERY

Patellar Luxation

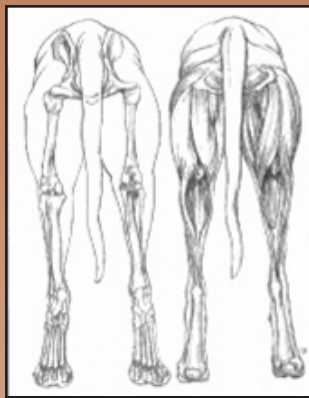What is a Patellar Luxation?

Patellar luxations (dislocation of the kneecap) occur frequently in dogs and rarely in cats. Patellar luxations can be grouped into two main categories. First, and most commonly, are the medially luxating patellas (MLP) which are congenital (existing from birth) and commonly affect smaller breed dogs, and to a lesser extent, cats. Dogs and cats with a medial patellar luxation will dislocate their patella towards the inside of the knee joint (figure 1). The second type are laterally luxating patellas which are often the result of trauma and can affect any pet. Animals with a lateral patellar luxation will dislocate their patella towards the outside of the knee joint (figure 2). Lameness occurs as the patella luxates, but lameness often spontaneously resolves when the patella returns to its normal position. Some animals learn to reposition the patella themselves by extending the hip and knee together behind them.

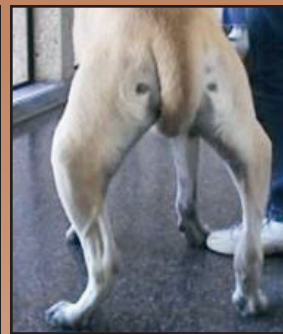
Diagnosis is made based on physical examination and may be confirmed with radiographs. Radiographs will demonstrate the patellar luxation if the patella is dislocated at the time the radiographs are taken. All animals with patellar luxations can develop some degree of arthritis whether or not surgery is performed.

Anatomy

The patella normally moves up and down in a groove in the lower femur, called the trochlear groove. In patellar luxation the groove is often shallow. This shallow groove prevents the patella from seating deeply and predisposes it to dislocation, which results in the luxation of the patella as the leg is used. The muscle groups of the thigh (quadriceps or extensor muscles) are associated with the patella. In patellar luxation, the extensor muscles are often misaligned to the inside or outside of the leg, which can contribute to the severity of the luxation. The degree of patellar luxation is graded from I to IV, depending on the relative ease with which the patella luxates. Grade I is the mildest and Grade IV is the most severe. Grade I and grade II patellar luxations may be incidental findings in mature cats and dogs that have never been lame. Grade III and IV MLP patients are usually lame. Severe cases may develop abnormal growth of the long bones of the leg, or may limit function.



Normal hind limb stance



"Bow-legged" stance resulting from medial patellar luxations.

Is Surgery Necessary?

The decision to perform surgery on animals with patellar luxations is based on many factors including the degree of lameness, the grade of patellar luxation, the age of the animal, and the presence of concurrent problems with the knee.

As previously discussed, some animals with patellar luxation exhibit little or no lameness. Oftentimes, a low grade MLP (which has been present all of the animal's life) is noted on routine physical examination, without any history of lameness. In these cases, surgery is not indicated. There is no increased incidence of ligament injuries in knees with luxating patellas. Surgery is performed to improve function, so if the animal is not lame then surgery is not indicated.

If the degree of patellar luxation is high (some grade II, and all of grade III and grade IV), your veterinarian will likely suggest surgery as soon as your pet can tolerate the procedure. In growing animals, severe patellar luxation may result in a crippling deformity of the leg. In older animals with higher grade patellar

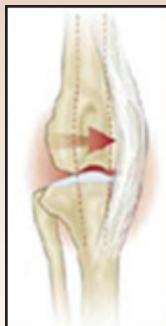

figure 1

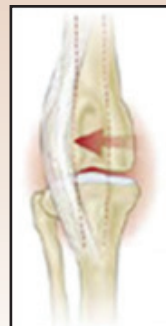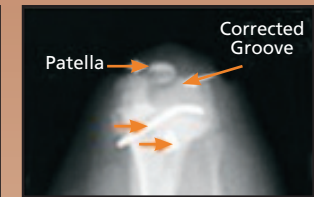
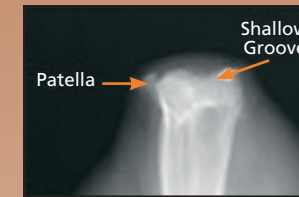


figure 2

This is how medial and lateral patellar luxations occur.

luxations, lameness is often present and surgery should improve function of the leg.

Patellar luxations may also be found in conjunction with other injuries of the knee. The most common concurrent injury is a rupture of the cranial cruciate ligament. Often the surgeon will discuss correction of the patellar luxation at the same time other injuries are repaired.



Surgical Techniques

Most surgical corrections of patellar luxations consist of deepening the groove in which the patella rides, tightening the tissues surrounding the knee joint, and moving the bone on which the patellar ligament inserts.

Deepening the groove (trochleoplasty) can be accomplished in several ways, depending on the age and size of the patient. By deepening the groove, the patella is less likely to move into an abnormal position. This is usually combined with other techniques to maximize stability of the knee.

When the patella is returned to its normal position, the soft tissues (retinaculum) around it will be loose on one side, and tight on the other. The surgeon will therefore tighten the soft tissues on the loosened side to hold the patella in place, and release or loosen the tissues on the opposite side.

The insertion of the patellar ligament on the tibia or shin bone may require repositioning (tibial tuberosity transposition). Because bone heals better than ligament, the bone is cut with the ligament attached, and secured with 1-2 small pins to a more normal location. This procedure is usually necessary for grade III and IV MLP.

Not every case requires the use of all these techniques. Each case is individually assessed, and often the final decision is made at the time of surgery.

